

## SHORT COMMUNICATION

## Inflammatory Epidermolysis Bullosa Acquisita Effectively Treated with Minocycline

Kana Kawase, Yoko Oshitani, Yoko Mizutani, En Shu, Etsuko Fujine and Mariko Seishima\*

Department of Dermatology, Gifu University Graduate School of Medicine, 1-1 Yanagido, Gifu 501-1194, Japan. \*E-mail: marikoseishima@yahoo.co.jp  
Accepted Jan 8, 2014; Epub ahead of print Feb 27, 2014

Epidermolysis bullosa acquisita (EBA) is an autoimmune mechanobullous disease that is clinically characterised by blisters and erosions on the skin and mucous membranes (1). Patients with EBA exhibit autoantibodies to type VII collagen (2) and are usually treated with corticosteroids, immunosuppressive agents, colchicine, diaphenylsulfone (DDS), or intravenous immunoglobulin (IVIG); however, to our knowledge, minocycline has not been reported to be effective in such cases. In the present report, we describe a patient with EBA who was initially treated with corticosteroids, and then successfully treated with minocycline for recurrence of EBA following corticosteroid dose reduction. The histological examination of the skin eruptions indicated subepidermal bulla formation as well as infiltration of lymphocytes, eosinophils and neutrophils in the upper dermis. As minocycline is known to inhibit neutrophil and eosinophil recruitment as well as cytokine production, it may be considered as a therapeutic option for EBA, particularly in cases exhibiting infiltration within the skin lesion on histological examination.

## CASE REPORT

A 71-year-old Japanese woman, weighing 44 kg, presented with a 1-month history of many bullae with slight itch on the skin over her entire body (Fig. 1a) and on the tongue (Fig. 1b) and oral mucosa. She had no history of allergy, and the laboratory data were within the normal ranges, including the leucocyte count (6,390/ $\mu$ l; normal range: 3,000–7,900/ $\mu$ l), eosinophil count (198/ $\mu$ l; normal 100–500/ $\mu$ l) and IgG concentration (1,188 mg/dL; normal 890–1,850 mg/dL). Antinuclear antibodies were negative. Histological examination indicated subepidermal bulla formation along with infiltration of lymphocytes, eosinophils, and a small amount of neutrophils in the upper dermis (Fig. 1c and d). Direct immunofluorescence (IF) examination of a biopsy specimen from erythema indicated the deposition of immunoglobulin (Ig) G and C3 at the basement membrane zone with u-serrated pattern (3). Indirect IF using 1 M NaCl-split normal human skin sections showed IgG anti-basement membrane zone antibodies, which reacted with the dermal side. Using an enzyme-linked immunosorbent assay (ELISA: MBL, Nagoya, Japan), the titres of IgG antibody to type VII collagen were 76.7 and 146.6, at the first consultation and 2 weeks after the first consultation, respectively (Fig. 2). Antibodies to desmoglein 1 and 3, bullous pemphigoid (BP) 180, and BP 230 were not detected in the patient's serum by ELISA. Based on the clinical features, histopathological findings, IgG deposition at the basement membrane zone, and presence of IgG antibodies to type VII collagen in serum, we diagnosed the patient with EBA. Although the patient was then treated with prednisolone (45 mg/day), the new development of bullae was still noted. The addition of cyclosporine (150 mg/day) to the regimen inhibited the formation of new bullae, and the prednisolone dose could be gradually reduced. However, during this dose reduction period, when the patient was being treated with 35 mg/day of prednisolone and 150 mg/day of cyclosporine, the formation of bullae increased. The addition of DDS (75 mg/day) to the treatment regimen was effective, and the bullae disappeared. However, the erythrocyte count and haemoglobin level in peripheral blood gradually decreased to  $231 \times 10^4/\mu$ l and 8.1 g/dl at 12 days after DDS therapy was initiated; the alanine transaminase level at this time increased to 79 IU/l. We suspected the presence of haemolytic anaemia and liver dysfunction as a result of the DDS therapy, and therefore, DDS was discontinued. Several bullae appeared again at 7 days after the discontinuation of DDS therapy. The abnormal blood data returned to the normal range after 13 days without any treatment. Following the addition of minocycline (200 mg/day) to the regimen, no new bullae developed, and the prednisolone dose could be reduced to 17.5 mg/day. In addition, no adverse effects as a result of minocycline therapy were observed.

Due to the lack of an index for the clinical disease activity in EBA, the disease activity in the present case was assessed according to the pemphigus disease

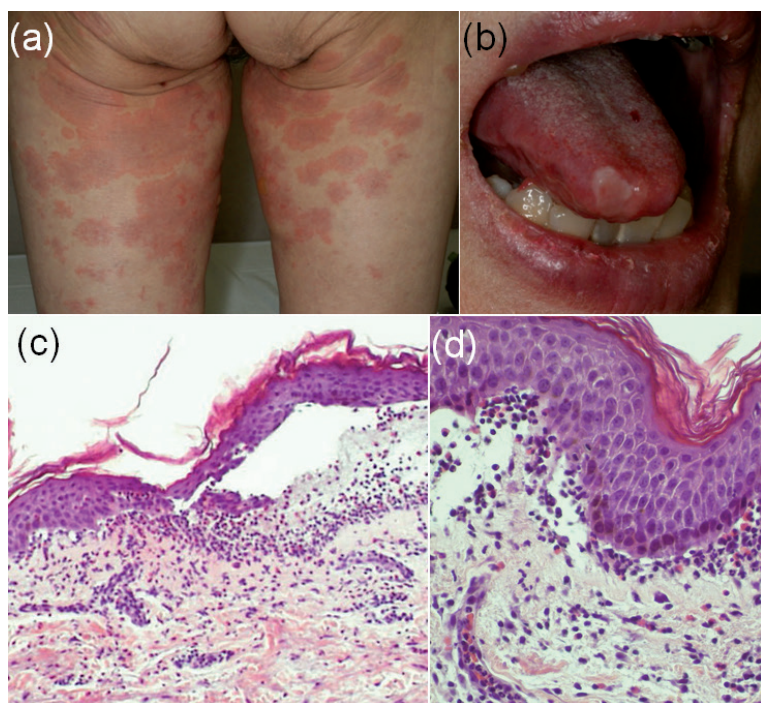


Fig. 1. Clinical features (a, b), and histopathological findings (c, d) at the first consultation. Multiple erosions and blisters on the skin of bilateral thigh (a), and on the tongue (b). A subepidermal blister with lymphocyte and neutrophil infiltration in the upper dermis (haematoxylin and eosin stain; original magnification, c:  $\times 200$  and d:  $\times 400$ ).

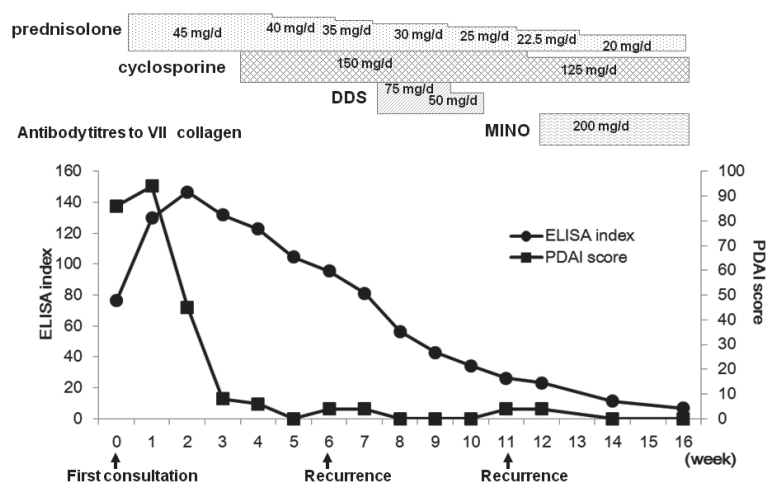


Fig. 2. The clinical course of the patient depicting the pemphigus disease area index (PDAI), antibody titre against type VII collagen (enzyme-linked immunosorbent assay (ELISA) index) and treatments. DDS: diaphenylsulfone, MINO: minocycline.

area index (PDAI), which is usually applied to pemphigus patients (4). In the present case, the highest PDAI score noted during the course of treatment was 94 points; the PDI score decreased to 0 point at 5 weeks post-treatment, but increased at the time of recurrence after 6 and 11 weeks. However, the titres of antibodies to type VII collagen gradually decreased without any subsequent elevation throughout the clinical course.

## DISCUSSION

No controlled clinical trials on the treatment of EBA have been performed as the prevalence of EBA is relatively low (1). Patients with EBA are generally treated with corticosteroids, immunosuppressive agents, colchicine, DDS, or IVIG. ELISA index scores for collagen VII antibodies are useful for determining the appropriate dose schedule of corticosteroids and for therapeutic planning (5). In the present case, the patient was initially treated with prednisolone, and additionally received cyclosporine treatment. However, due to the formation of new bullae following reduction of the prednisolone dose, DDS was added to the regimen, which effectively inhibited bulla formation. DDS was discontinued because of the development of haemolytic anaemia and liver dysfunction, and minocycline was subsequently administered as an adjuvant therapy.

Minocycline is a broad-spectrum tetracycline antibiotic that is reportedly effective in autoimmune bullous diseases such as bullous pemphigoid (6) and pemphigus (7). In the present case, minocycline was effective for treating the patient, and prednisolone dose could gradually be reduced. Although the mechanisms underlying the efficacy of minocycline in autoimmune bullous diseases have not been fully clarified, minocycline is considered to inhibit neutrophil and eosinophil recruitment, inhibit collagenases and proteases (8), and block antibody formation (6). In addition, minocycline reportedly inhibits the production of cytokines such as tumour necrosis factor- $\alpha$ , interleukin-6, interferon- $\gamma$ , C-X-C motif chemokine (CXCL)

8, CXCL10, C-C motif chemokine (CCL) 2, CCL3, CCL4, CCL5, and CCL11 via the inhibition of I $\kappa$ B kinase  $\alpha/\beta$  phosphorylation (9). We could not clarify whether minocycline showed any effects on the inhibition of autoantibody production as the titre of antibody to type VII collagen gradually decreased, even during the periods of recurrence, in the present case (Fig. 2). Patients with EBA usually present with a non- or pauci-inflammatory subepidermal blister, whereas those with the inflammatory forms of EBA present with neutrophil-rich infiltration with variable numbers of eosinophils and mononuclear cells (2, 10). In our patient infiltration of lymphocytes and eosinophils was detected on histological examination. Based on these findings, we believe that minocycline may have been effective in the present case, possibly by inhibiting inflammation, but not autoantibody

production. Thus, minocycline can serve as a therapeutic option for EBA, particularly as an adjuvant therapy in cases with the inflammatory form of EBA.

*The authors declare no conflict of interest.*

## REFERENCES

- Ludwig RJ. Clinical presentation, pathogenesis, diagnosis, and treatment of epidermolysis bullosa acquisita. *ISRN Dermatology* 2013; 812029, 1–25.
- Woodley DT, Chang C, Saadat P, Ram R, Liu Z, Chen M. Evidence that anti-type VII collagen antibodies are pathogenic and responsible for the clinical, histological, and immunological features of epidermolysis bullosa acquisita. *J Invest Dermatol* 2005; 124: 958–964.
- Buijsrogge JJA, Diercks GFH, Pas HH, Jonkman MF. The many faces of epidermolysis bullosa acquisita after serration pattern analysis by direct immunofluorescence microscopy. *Br J Dermatol* 2011; 165: 92–98.
- Rosenbach M, Murrell D, Bystryk J-C, Dulay S, Dick S, Fakharzadeh S, et al. Reliability and convergent validity of two outcome instruments for pemphigus. *J Invest Dermatol* 2009; 129: 2404–2410.
- Sato M, Ishitsuka A, Shibuya Y, Kanoh H, Koga H, Hashimoto T, et al. Time-course of the change in titre of antibodies against type VII collagen in a patient with epidermolysis bullosa acquisita. *Acta Derm Venereol* 2012; 92: 693–694.
- Loo WJ, Kirschig G, Wojnarowska F. Minocycline as a therapeutic option in bullous pemphigoid. *Clin Exp Dermatol* 2001; 26: 376–379.
- Calebotta A, Sáenz AM, González F, Carvalho M, Castillo R. Pemphigus vulgaris: benefits of tetracycline as adjuvant therapy in a series of thirteen patients. *Int J Dermatol* 1999; 38: 217–221.
- Aminov RI. Biotic acts of antibiotics. *Front Microbiol* 2013; 4: 241.
- Tai K, Iwasaki H, Ikegaya S, Ueda T. Minocycline modulates cytokine and chemokine production in lipopolysaccharide-stimulated THP-1 monocytic cells by inhibiting I $\kappa$ B kinase  $\alpha/\beta$  phosphorylation. *Transl Res* 2013; 161: 99–109.
- Ishii N, Hamada T, Dainichi T, Karashima T, Nakama T, Yasumoto S, et al. Epidermolysis bullosa acquisita: what's new? *J Dermatol* 2010; 37: 220–230.